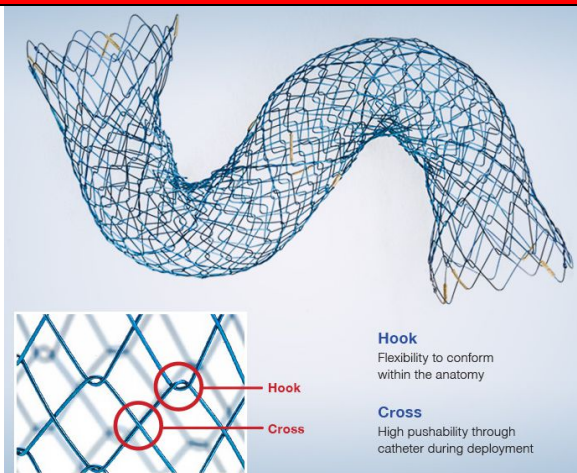


**RAPID HTA REVIEW**

N° richiesta	Data richiesta	Richiedente
194	27/04/2021	Gastroenterologia ed Endoscopia Digestiva – Ospedale di Pistoia

Dati generali della tecnologia in valutazione

Nome commerciale			
HANAROSTENT BMCL			
Nome generico			
Stent totalmente ricoperto per la stenosi del dotto biliare			
Nome fabbricante			
M.I. Tech Co. Ltd			
Nome fornitore			
Olympus Italia srl			
RDM	REF		
Vari	1657336		
Tipo	Marchio CE (data)	Classe di rischio	Approvazione FDA
1	2005	IIb	Si
CND			
P0502 (Protesi biliari e pancreatiche)			
Campo di applicazione			
Endoscopia digestiva			
Paziente target			
Pazienti con colecisti funzionante affetti da stenosi neoplastica o non neoplastica della via biliare.			
Indicazione d'uso			
Hanorestent BMCL è indicato per il trattamento palliativo di stenosi del dotto biliare causate da tumore maligno e/o benigno.			
Principali competitor			
Stent non ricoperti in caso di stenosi neoplastica; protesi plastiche in caso di stenosi benigne.			

Dettagli tecnologici**Descrizione**

Hanarostent è una protesi in nitinolo autoespandibile totalmente ricoperta. La protesi ha un design Multi-Hole (presenza di fori nella copertura in silicone) che conferisce alla protesi elevate proprietà di conformabilità. Inoltre, tale conformazione permette di conservare la pervietà del lume e assicura un elevato incremento dell'efficienza del drenaggio. A riposo la protesi è compressa nel suo sistema di rilascio. Le maglie in nitinol si espandono durante il posizionamento e la protesi assume progressivamente la sua configurazione finale. La combinazione tra forza radiale e assiale data dal design Cross&Hook assicura un'alta flessibilità nel conformarsi all'anatomia e contemporaneamente permette di conservare la pervietà del lume. Il design Cross&Hook permette inoltre di ridurre al minimo l'accorciamento della protesi dopo il posizionamento ed evita gli effetti di migrazione e dislocazione. Il rivestimento della protesi è in silicone che evita la ricrescita tissutale attraverso le



maglie dello stent. La protesi è montata su un sistema di rilascio TTS (Through The Scope).

Elementi di innovazione

Presenza di fori in nitinolo sulla copertura che permettono un miglior drenaggio della bile con riduzione di complicanze (ad esempio idrope della colecisti in pazienti con colecisti funzionante).

Evidenze cliniche ed economiche

Studi clinici

Una ricerca PubMed condotta il 30 Giugno 2021 (parola chiave "Hanarostent") ha selezionato 18 studi. Il dispositivo è supportato da una notevole letteratura sia per l'uso in patologie del tratto gastrointestinale sia in altre sedi anatomiche. Vi sono studi anche in riferimento all'uso nel distretto pancreatico/biliare.

Nella Appendice Bibliografica a fine scheda sono riportati gli abstract dei principali gli studi clinici.

Sperimentazioni cliniche

Si tratta di un'informazione non di particolare rilievo, vista la letteratura robusta già disponibile su questo dispositivo.

Linee guida

Non disponibili.

Analisi di costo-efficacia

Non disponibili.

Report HTA

Non disponibili.

Benefici attesi

Drenaggio della bile e riduzione delle complicanze.

Prezzo e costo terapia per paziente

Prodotto (Fabbricante)	Prezzo unitario (euro)	Costo terapia per paziente (euro)
Hanarostent BMCL (Olympus)	Circa 1000 euro	Circa 1000 euro

Prezzo e costo terapia per paziente con le alternative terapeutiche già in uso

Prodotto (Fabbricante)	Prezzo unitario (euro)	Costo terapia per paziente (euro)
Stent non ricoperti (Boston ed Euromedical)	Circa 1.200	Circa 1.200

Rimborso procedura legata all'uso del dispositivo medico richiesto

Codice ICD9-CM di diagnosi principale (descrizione)	Codice ICD9-CM di intervento (descrizione)	Codice DRG (descrizione)	Tariffa (euro)
155.1, 157.0	51.87	203	4085



Dati riassuntivi		
Numero richiesta	Data richiesta	Richiedente
194	27/4/2021	USLCENTRO (Ospedale di Pistoia)
Tecnologia in valutazione		
-		
Eventuali esperti esterni coinvolti		
-		
Conclusioni e parere del Gruppo di lavoro Regionale permanente sui Dispositivi Medici (GRDM)		
Parere favorevole		
Data di redazione della scheda		
2 Luglio 2021		
Estensore della scheda		
Andrea Messori		
Farmacista aziendale referente per la richiesta		
Sara Bellugi		
Decisione della Commissione per la valutazione delle tecnologie e degli investimenti sanitari (C-HTA)		
Parere sfavorevole. Il prodotto non è stato offerto in gara		
Data della decisione della C-HTA		
15/07/2021		

BIBLIOGRAFIA

Si rimanda alla Appendice Bibliografica riportata più avanti.

Copia del documento può essere scaricata dal sito Internet <http://www.regione.toscana.it/-/prodotti-hta>.

Redazione a cura del Gruppo di Lavoro Regionale Permanente sui Dispositivi Medici, Decreto n.7468 del 17-05-2018.



APPENDICE BIBLIOGRAFICA

J Crohns Colitis. 2021 Apr 6;15(4):521-528. doi: 10.1093/ecco-jcc/jjaa208.

An Anti-migration Self-expandable and Removable Metal Stent for Crohn's Disease Strictures: A Nationwide Study From GETAID and SFED

Alain Attar¹, Julien Branche², Emmanuel Coron³, Jocelyn Privat⁴, Ludovic Caillio⁵, Jean-Baptiste Chevaux⁶, Lucine Vuitton⁷, Aurélien Amiot⁸, Hichem Belkhdja⁹, Xavier Dray¹⁰, Thierry Ponchon¹¹, Yoram Bouhnik¹, Cédric Baumann¹², Laurent Peyrin-Biroulet⁵

Abstract

Background and aims: In Crohn's disease, strictures are frequent and may require surgical resection or endoscopic balloon dilation. An anti-migration, removable and shaped self-expandable metal stent is available. We evaluated its effectiveness and safety in a real-life setting.

Methods: All centres were asked to collect retrospectively or prospectively all data on patients who had a stent for a stricture. The anti-migration stent [Hanarostent HRC-20-080-230-MITech, Seoul, South Korea] was maintained 7 days before its extraction during a second colonoscopy. Short- and long-term efficacy and safety outcomes were evaluated.

Results: A total of 46 patients were enrolled. Strictures were anastomotic in 73.9% of cases. The median length of the stricture evaluated by cross-sectional imaging and during colonoscopy was 3.1 ± 1.7 and 2.7 ± 1.4 cm, respectively. Immediate success [no obstructive symptom at Day 30] was reported in 93.5% of cases (95% confidence interval [CI] = [86.3; 99.9]). Sixteen patients needed a new balloon dilation [n = 8] or surgery [n = 8]. The overall success rate [obstruction-free without any intervention] was 58.7% [n = 27] after a median follow-up of 26 months [8-41 months]. No perforation occurred and three migrations were observed [6.5%]. Perianal disease (hazard ratio [HR] = 0.1 [0.02; 0.58]) and discontinuation of an immunosuppressant (0.12 [0.02; 0.86]), were associated with a lower probability of success, whereas performing imaging (HR = 5.3 [1.2; 23.5]) before stent placement was associated with success.

Conclusions: The anti-migration stent is safe and effective in about half of patients, with no perforation reported in this study, and has an extremely low migration rate.



Surg Technol Int. 2018 Nov 11;33:111-118.

Management of Staple Line Leaks Following Laparoscopic Sleeve Gastrectomy for Morbid Obesity

Giuseppe Currò¹, Iman Komaei¹, Claudio Lazzara¹, Federica Sarra¹, Andrea Cogliandolo¹, Saverio Latteri², Giuseppe Navarra¹

Abstract

Purposes: Management of staple-line leaks following laparoscopic sleeve gastrectomy (LSG) is challenging and controversial. Guidelines for leak treatment are not standardized and often involve multidisciplinary management by surgical, medical and radiological methods. Herein we present our experience and proposed strategy for handling leaks after LSG.

Patients and methods: Retrospective data regarding LSG performed from April 2012 to October 2017 at the Surgical Oncology Division, Department of Human Pathology in Adulthood and Childhood "G. Barresi", University Hospital "G. Martino", University of Messina, Italy, were reviewed. The management approaches and the surgical, endoscopic, and percutaneous procedures used were examined. Outcomes measured included the prevalence of gastric leaks, radiological features, related morbidities and mortalities, hospital stay and management.

Results: LSG was performed in 310 patients. Eight patients were managed for gastric leak within the 5-year period: 5 (1.6% overall prevalence) from our division, 3 referred from another hospital. All cases were successfully treated conservatively with combined CT/US-guided drainage using a locking pigtail catheter and endoscopic gastric stent positioning. Endoscopic therapy included the use of fully covered self-expanding esophageal metal stents (Hanarostent® 24 cm; M.I. Tech, Seoul, Korea) in addition to pigtail drains (Drainage Catheter Locking Pigtail 8F/21cm; Tru-Set® Ure-Sil, Skokie, IL, USA). Complete closure of the leak was achieved in all patients. The mean time from presentation to healing was 74 days \pm 37.76 (SD). None of the patients underwent remedial surgery.

Conclusion: This study presents our management strategy for leak resolution in LSG patients. Based on our results, we strongly recommend the conservative and combined management of gastric leaks following LSG by endoscopic stenting and percutaneous drainage.

GE Port J Gastroenterol. 2017 Jul;24(4):169-175. doi: 10.1159/000453115. Epub 2016 Dec 21.

Treatment of Postoperative Leaks of the Upper Gastrointestinal Tract with Colonic Self-Expandable Metal Stents

Paula Sousa¹, António Castanheira¹, Diana Martins¹, Juliana Pinho¹, Ricardo Araújo¹, Eugénia Cancela¹, Paula Ministro¹, Américo Silva¹

Abstract

in English, Portuguese

Introduction: The use of self-expandable metal stents (SEMS) for the treatment of postoperative leaks of the upper gastrointestinal tract is already established. However, there are discrepancies between the relatively small caliber of the esophageal stents available and the postsurgical luminal size, which may determine an inadequate juxtaposition. As colonic stents have a bigger diameter, they might be more adequate. Additionally, stents with a larger diameter might have a lower risk of migration.

Materials and methods: The aim of this study was to evaluate the efficacy and complications associated with the use of colonic fully covered SEMS (FSEMS) in the treatment of postoperative leaks in critical patients. All patients with postoperative leaks of the upper gastrointestinal tract treated with colonic stents (Hanarostent® CCI) between 2010 and 2013 were retrospectively included.

Results: Four patients with postoperative leaks were treated with colonic SEMS. The underlying surgeries were a



gastric bypass, an esophagogastrectomy for Boerhaave syndrome, a primary repair of esophagopleural fistula due to Boerhaave syndrome, and an esophagectomy due to esophageal cancer. The leaks were detected on average 17 days after the initial surgery. All patients needed admission to a critical care unit after index surgery. Stent placement was technically feasible in all patients. The median residence time of the stents was 7 weeks, and no complications were verified when they were removed. There were no cases of stent migration. The treatment was successful in all patients, with complete healing of the leaks.

Discussion and conclusions: The placement of colonic FSEMS seems to be successful and safe in the treatment of postoperative leaks of the upper gastrointestinal tract.

Surg Endosc. 2018 May;32(5):2448-2453. doi: 10.1007/s00464-017-5946-6. Epub 2017 Nov 3.

Comparison of clinical efficacies and safeties of lumen-apposing metal stent and conventional-type metal stent-assisted EUS-guided pancreatic wall-off necrosis drainage: a real-life experience in a tertiary hospital

Siu Tong Law¹, Carlos De La SernaHiguera², Paula Gil Simón², Manuel Pérez-MirandaCastillo²

Abstract

Background: Endoscopic ultrasound (EUS)-guided drainage of pancreatic wall-off necrosis (WON) with transmural stent is regarded as firstline therapy. We aimed at comparing its efficacy and safety with using fully covered self-expandable metal stent (FCSEMS) and lumen-apposing metal stent (LAMS).

Methods: A retrospective review was performed on all consecutive patients with pancreatic WONs who underwent EUS-guided drainage by either FCSEMS or LAMS.

Results: From 2011 to 2016, 68 patients (66.2% male, median age, 66.5 years) underwent WON drainage (22/68 (32.4%) using FCSEMSs of size 10 × 60 mm (14/22, Hanarostent; 8/22 Wallflex); 46/68 (67.6%) using LAMSs (38/46 and 8/46 with AXIOS of size 15 × 10 mm and 10 × 10 mm, respectively). These two groups were matched for age (66 vs. 70 years, p 0.514), APACHE II (11.5 vs. 10, p 0.693), causes [72.7 vs. 80.4% by gallstone pancreatitis (p 0.472); 9.1 vs. 10.9% by alcoholism (p 0.818)], WON size (8.5 vs. 9 cm, p 0.322), location (36.4 vs. 26.1% at pancreatic head, p 0.384; 54.5 vs. 65.2% at body/tail, p 0.395), and enterostomy site [63.6 vs. 76.1% via transgastric (p 0.285); 31.8 vs. 19.6% via transduodenal (p 0.267)] and their number of necrosectomy (p 0.978). The technical (100 vs. 93.5%, p 0.219) and clinical (95.5 vs. 93.5%, p 0.749) success and adverse event (22.7 vs. 39.1%, p 0.180; 9.1 vs. 19.6% with bleeding, p 0.271; 4.5 vs. 13% with spontaneous stent migration, p 0.28; 9.1 vs. 6.5% with dislodgement during necrosectomy, p 0.704) of the two groups were comparable without significant different. However, the LAMS group associated with early stent revision compared with FCSEMS group (log rank p 0.048). Conclusions: EUS-guided drainage of WON using FCSEMSs and LAMSs are comparable in efficacy and safety; however, the latter is associated with early stent revision.

World J Gastrointest Endosc. 2017 Jun 16;9(6):267-272. doi: 10.4253/wjge.v9.i6.267.

Utility of the balloon-overtube-assisted modified over-the-wire stenting technique to treat post-sleeve gastrectomy complications

Ana Ponte¹, Rolando Pinho¹, Luísa Proença¹, Joana Silva¹, Jaime Rodrigues¹, Mafalda Sousa¹, João Carlos Silva¹, João Carvalho¹

Abstract

Aim: To describe a modified technique of deployment of stents using the overtube developed for balloon-assisted enteroscopy in post-sleeve gastrectomy (SG) complications.



Methods: Between January 2010 and December 2015, all patients submitted to an endoscopic stenting procedure to treat a post-SG stenosis or leakage were retrospectively collected. Procedures from patients in which the stent was deployed using the balloon-overtube-assisted modified over-the-wire (OTW) stenting technique were described. The technical success, corresponding to proper placement of the stent in the stomach resulting in exclusion of the SG leak or the stenosis, was evaluated. Complications related to stenting were also reported.

Results: Five procedures were included to treat 2 staple line leaks and 3 stenoses. Two types of stents were used, including a fully covered self-expandable metal stent designed for the SG anatomy (Hanarostent, ECBB-30-240-090; M.I. Tech, Co., Ltd, Seoul, South Korea) in 4 procedures and a biodegradable stent (BD stent 019-10A-25/20/25-080, SX-ELLA, Hradec Kralove, Czech Republic) in the remaining procedure. In all cases, an overtube was advanced with the endoscope through the SG to the duodenum. After placement of the guidewire and removal of the endoscope, the stent was easily advanced through the overtube. The overtube was pulled back and the stent was successfully deployed under fluoroscopic guidance. Technical success was achieved in all patients.

Conclusion: The adoption of a modified technique of deployment of OTW stents using an overtube may represent an effective option in the approach of SG complications.

Rev Esp Enferm Dig. 2017 May;109(5):376.

An unusual cause of Boerhaave's syndrome in a young patient

Samuel Fernandes¹, Carlos Noronha Ferreira¹, José Freire², José Velosa³

Abstract

An 18-year-old male patient with a history of atopy and intermittent dysphagia for solids, presented to the emergency department with sudden onset total dysphagia followed by hematemesis, after ingesting an ibuprofen tablet. Urgent upper gastrointestinal endoscopy revealed a deep laceration just above the tablet impacted in the distal esophagus. Abdominal CT-scan confirmed the suspicion of an esophageal perforation. The impacted tablet was broken up with biopsy forceps, and a covered metallic stent (Hanarostent® 60/100x20/26mm) was placed across the cardia effectively excluding the fistula. Recovery was uneventful and the stent was easily removed 6 weeks later. Follow-up biopsies showed marked mucosal infiltration by eosinophils confirming the diagnosis of eosinophilic esophagitis (EE). The patient was treated with oral budesonide and remains asymptomatic.



Eur J Cardiothorac Surg. 2017 Sep 1;52(3):601-603. doi: 10.1093/ejcts/ezx118.

Primary chondrosarcoma of the trachea with extensive extraluminal growth

Andrey Ryabov¹, Oleg Pikin², Victor Sokolov³, Nadezda Volchenko⁴

Abstract

Primary chondrosarcoma of the trachea is an extremely rare non-epithelial neoplasm with only few cases published in the literature. We present a rare case of tracheal chondrosarcoma with extensive extraluminal growth. We operated a patient with obstructive tumour of the upper third of the trachea via partial sternotomy. Before surgery, a Hanarostent was put into the trachea to treat a life-threatening stenosis. Postoperative period was uneventful. We discuss the incidence, clinical presentation and treatment options in patients with rare tracheal tumours. In some cases, a multidisciplinary approach (endoscopic intervention followed by surgical resection) is an effective treatment tool.

Obes Surg. 2016 Aug;26(8):1875-80. doi: 10.1007/s11695-015-2027-6.

A Specifically Designed Stent for Anastomotic Leaks after Bariatric Surgery: Experiences in a Tertiary Referral Hospital

Martin R van Wezenbeek^{1,2}, Martine M de Milliano³, Simon W Nienhuijs⁴, Pieter Friederich³, Lennard P L Gilissen³

Abstract

Background: The management of anastomotic leakage after either laparoscopic Roux-en-Y gastric bypass (LGBP) or laparoscopic sleeve gastrectomy (LSG) remains a burden. Various options are available for the treatment of these leaks. A newer and less invasive option for the treatment of leaks is the use of endoluminal stents. The main drawback for this treatment is stent migration. The current study describes the outcome of a new, specifically designed stent for the treatment of anastomotic leaks after bariatric surgery.

Methods: For this retrospective observational study, the medical charts of patients undergoing bariatric surgery between October 1, 2010 and July 1, 2013 were reviewed. All patients with anastomotic leakage, treated with the bariatric Hanarostent, were included.

Results: Twelve patients were included out of a total of 1702 bariatric patients in the described period. Seven had a leakage after LSG, five after LGBP. An average of 2.4 endoscopic procedures and 1.25 stents were used per patient. Successful treatment was seen in nine out of 12 patients (75 %). Most common complication was dislocation or migration of the stent, occurring in eight patients (66.7 %).

Conclusions: The ECBB Hanarostent®, which was specifically designed for post bariatric leakages, shows equal but not favorable success rates in this small series compared to previous reports on other types of stenting techniques. Despite the stent design, the complication rate is not reduced and the main future goal should be to target the high stent migration rate.